


# The Use of Platelet-Rich Plasma in Aesthetic and Regenerative Medicine: A Comprehensive Review

Pouria Samadi<sup>1</sup> · Mohsen Sheykhasan<sup>1,2</sup>  · Hamed Manoochehri Khoshinani<sup>1</sup>



Received: 27 September 2018 / Accepted: 24 November 2018 / Published online: 14 December 2018  
© Springer Science+Business Media, LLC, part of Springer Nature and International Society of Aesthetic Plastic Surgery 2018

## Abstract

**Introduction** In recent years, platelet-rich plasma (PRP) has emerged as a promising autologous biological treatment modality for the use in aesthetic and regenerative medicine. PRP is a high concentration of platelets derived from whole blood which is isolated by centrifugation to separate and concentrate platelet-containing plasma from red blood cells. PRP comprises hundreds of bioactive proteins, including growth factors, peptides, and cytokines that stimulate healing of skin and soft tissues. Attractive features of PRP are the extended release of various growth and differentiation factors from activated platelets, tissue regenerative, and healing capabilities, as well as the lack of problems associated with immunogenicity. Because of the unique biological features of this whole blood-derived biological agent, multiple clinical uses for PRP exist for aesthetic and regenerative medicine.

**Evidence Acquisitions** A comprehensive review of the literature regarding the use of platelet-rich plasma in aesthetic and regenerative medicine was performed.

**Evidence Synthesis** Therapeutic applications of PRP including several methods for its clinical deployment in conditions related to aesthetic and regenerative medicine including wound healing, skin and facial rejuvenation, hair

restoration, hand rejuvenation, breast augmentation, and musculoskeletal regeneration were reviewed.

**Conclusion** PRP treatment has shown itself as a bright future for a safe and efficient cosmetic intervention. However, more studies are needed to better our understanding of limitations and benefits in clinical phases associated with the aesthetic use of PRP.

**Level of Evidence III** This journal requires that authors assign a level of evidence to each article. For a full description of these Evidence-Based Medicine ratings, please refer to the Table of Contents or the online Instructions to Authors [www.springer.com/00266](http://www.springer.com/00266).

**Keywords** Platelet-rich plasma · Autologous biological agent · Aesthetic medicine · Regenerative medicine · Skin · Soft tissue · Musculoskeletal tissue

## Abbreviations

PRP	Platelet-rich plasma
GF	Growth factor
VEGF	Vascular endothelial growth factor
PDGF	Platelet-derived growth factor
EGF	Epidermal growth factor
TGF- $\beta$	Transforming growth factor beta
FGF	Fibroblast growth factor
IGF-1	Insulin-like growth factor 1
PDEGF	Platelet-derived epidermal growth factor
PDAF	Platelet-derived angiogenesis factor
PF-4	Platelet factor 4
IL-1	Interleukin-1
I-A	Interferon alpha
I-G	Interferon gamma
AGA	Androgenetic alopecia

✉ Mohsen Sheykhasan  
mohsen.sh2009@gmail.com

<sup>1</sup> Department of Molecular Medicine and Genetics, Research Center for Molecular Medicine, Faculty of Medicine, Hamadan University of Medical Sciences, Hamadan, Iran

<sup>2</sup> Department of Mesenchymal Stem Cell, The Academic Center for Education, Culture and Research, Qom Branch, Qom, Iran

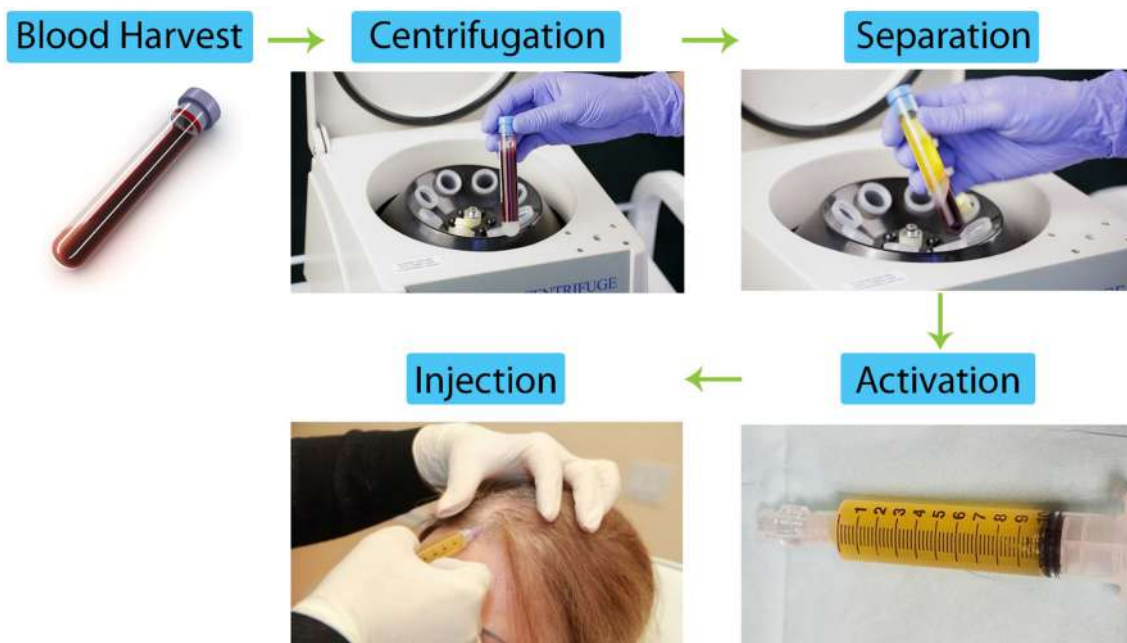## Introduction

Platelet-rich plasma (PRP) is an autologous blood-derived product comprised of high platelet concentrations and also other factors like coagulation factors obtained by simple and low cost methods of centrifugation [1]. Commercially available closed systems for isolating PRP are often preferable and could purify PRP 2–9 times higher than the baseline concentration, as well as providing more consistency and less variability with the isolated PRP product [2, 3].

There are several ways of preparing PRP including manual and mechanical procedures. In the manual method, PRP is obtained by collecting approximately 20 ml of whole blood and mixing it with 2 ml of anti-coagulation factor and then differential centrifugation of blood (double spin method), to remove red blood cells (RBC) at first (for instance, a soft spin of 200 g for 15 min); after that, there will be three layers: upper layer containing platelets including pure platelet-rich plasma (P-PRP), leucocyte and PRP (L-PRP), pure platelet-rich fibrin (P-PRF), and leucocyte- and platelet-rich fibrin (L-PRF) besides an intermediate layer that is known as the buffy coat, comprising white blood cells (WBC), and a bottom layer of RBCs (Fig. 1) [4]. Then to achieve pure PRP (P-PRP), the upper layer plus the buffy coat are transferred to another tube, without any anticoagulant, and platelets are concentrated at a higher speed of centrifugation (for instance, a hard spin of 400 g for 15 min) to form a soft pellet at the bottom, and then, by discarding the supernatant-containing PPP

(platelet-poor plasma) PRP remains, which is homogenized in lower quantity of (5 ml) PRP to yield a higher PRP concentration and also analysed for the presence of WBC and the integrity of the platelets [3, 5, 6]. Finally, calcium chloride ( $\text{CaCl}_2$ ) or thrombin can be used as an activator for degranulation of growth factors to yield activated PRP [7]. Therefore, in different manual methods the final quality and quantity of PRP might be changed. In the mechanical method of PRP preparation, there are many commercial PRP kits that facilitate the preparation of ready-to-apply platelet-rich suspensions in a reproducible manner. Although commercial kits are time-saving, they can be quite expensive as compared to the manual strategies. These kits and devices can be categorized into lower and higher systems with different baseline concentrations of 2.5–3 times and 5–9 times, respectively. Their difference is mainly depending on their ability to collect and concentrate platelets and the method and time of centrifugation. Therefore, due to the variations in the concentrations of platelets and WBC a diversity of growth factor concentrations is yielded [3, 8].

In general, to achieve a highly efficient PRP various protocols and procedures have been optimized with respect to different variables of the process, like number of spins, volume and sampling of processed WB, centrifugation time, and range of centrifugal acceleration. So, many optimizations in different steps could improve the final efficacy of concentrated PRP and it is advisable to standardize individual preparation protocols, which are cost-effective and easy to adapt in clinical settings [3, 9]. Here



**Fig. 1** Schematic illustration of the preparation of platelet-rich plasma (PRP)

in Table 1, there is a comparison of various protocols (manual and several commercial kits) for platelet yield, and despite these variations, each protocol follows several steps that consist of blood collection, first centrifugation to separate RBCs, second centrifugations to concentrate platelets and other components, and the activation of the sample by adding a platelet agonist.

Many studies have shown that platelets contain a vast variety of biologically active proteins, including vascular endothelial growth factor (VEGF), platelet-derived growth factor (PDGF), epidermal growth factor (EGF), transforming growth factor beta (TGF- $\beta$ ), fibroblast growth factor (FGF), and insulin-like growth factors (IGF-1, IGF-2). These biological factors can influence various cellular processes including homing of stem cells, cellular migration, proliferation, and differentiation, angiogenesis, macrophage activation, and collagen and matrix synthesis [10, 11]. Furthermore, these platelet-derived biological agents can affect the healing processes of damaged and wrinkled skin (skin rejuvenation), wound and scar rejuvenation, hand rejuvenation, musculoskeletal rejuvenation/regeneration, scalp hair regeneration, and breast augmentation [12–18].

The combination of low cost, easy, and fast isolation, without major side effects, and also its potential healing, immunomodulatory, and paracrine properties, makes PRP an attractive therapeutic modality for implementation in aesthetic and regenerative medicine [19–25].

Based on the mentioned evidences, this study aims to exclusively explore the evidence of effectiveness of the PRP clinical applications for various conditions related to aesthetic and regenerative medicine, including scar and

wound healing, skin and facial rejuvenation, hand rejuvenation, hair restoration, and breast augmentation across clinical studies.

## Evidence Acquisition

A comprehensive review of the literature in relation to the utilization of platelet-rich plasma in aesthetic and regenerative medicine was performed by searching PubMed/Medline and Cochrane databases. The following key terms were utilized to extract articles: platelet-rich plasma [MeSH Terms] OR platelet-rich plasma [All Fields]. Eligible studies involving the aesthetic and regenerative medicine use of PRP in human subjects only were included in this review to fulfil the inclusion criteria. After that, analysis of eligible studies was performed to assess study design, PRP dosage, and duration of follow-up.

## Evidence Synthesis

### Wound Healing

The clinical benefit of PRP as a leading treatment for healing of ulcers and wounds has been shown in numerous studies [26–30]. In general, wound healing is one of the sophisticated processes in advanced organisms involving various signalling pathways that are triggered by different cellular and chemical factors [31]. Typically, the wound healing process is divided into four overlapping stages of haemostasis, inflammation, proliferation (re-epithelialization), and remodelling or

**Table 1** Brief comparison between manual and commercial protocols for platelet yield

Preparation method	Volume of whole blood	Centrifugations first/second	Mean platelet count	Pros and cons
Temperature-controlled PRP; activation of PRP by incubation for 15 min at 37 °C [116]	10 ml	200 g for 10 min/ 1550 g for 10 min	6.58 $\pm$ 0.45-fold than whole blood (1156 $\pm$ 114 $\times$ 10 <sup>9</sup> /L)	More affordable and cost-effective
Single centrifugation technique [117]	8 ml	3200 RPM for 10 min	Sixfold than whole blood (1725 $\pm$ 773.8 $\times$ 10 <sup>9</sup> /L)	Inexpensive compared with commercial PRP kits (\$29)
Pro-PRP device	10 ml to 60 ml	NR	12-fold than whole blood	Higher PRP concentration but expensive (\$350 to \$800)
3E PRP kit	10 ml	3000 RPM for 10 min	8–12-fold than whole blood	Easy protocol, single centrifugation of highly enriched platelets, and cost-effective
Dr. PRP kit	20 ml	3000 RPM for 3 min/3200 RPM for 6 min	Up to 2000 $\times$ 10 <sup>9</sup> /L	Higher PRP concentration and less expensive (\$140)

NR not reported

maturation, which are regulated by a vast variety of factors [10]. Biological factors released by platelets within PRP that play crucial roles in healing processes include fibrin as a clotting agent and other factors that participate in different phases and including TGF- $\beta$ 1, TGF- $\beta$ 2, interleukin-1 (IL-1), IL-6, granulocyte colony-stimulating factor (G-CSF), TNF- $\alpha$ , PDGF-AA, PDGF-BB, PDGF-AB, FGF, platelet-derived epidermal growth factor (PDEGF), platelet-derived angiogenesis factor (PDAF), platelet factor 4 (PF-4), EGF, keratinocyte growth factor (KGF), hepatocyte growth factor (HGF), and (IGF-1, IGF-2) [32, 33]. Many of which could promote wound healing by inducing cell division through attracting undifferentiated cells to form a new matrix [23]. Furthermore, PRP by reducing inflammation through suppressing cytokine secretion may improve healing, regeneration, re-epithelialization, and angiogenesis of damaged and wounded tissues [34–36]. Another role of PRP is their defensive mechanism against some bacteria in the wound site, which reduces microbial infection [28].

### Skin and Facial Rejuvenation

As we age, processes like wound healing and cell replacement in the epidermis of the face decreases which results in saggy and wrinkled skin. At the cellular level, the most important promoter of skin ageing is decreasing the production of fibroblasts and collagen [37]. Furthermore, alterations in the interaction of these fibroblasts with other cells such as dermal mast cells, epidermal keratinocytes, and adipocytes are also critical during skin ageing [38]. The space between these cells is filled with extracellular matrix (ECM) proteins, cell adhesion molecules (CAMs), glycoproteins, cytokines, growth factors, etc., which by enhancing skin cell interactions to preserve their integrity and youthful appearance [39].

Continuous stimulation of collagen synthesis by various growth factors and cytokines is required for skin cell replacement processes. But during ageing, exposure of human skin to UV radiation and its incorporation with various macromolecules in skin (e.g. proteins, DNA, RNA, and vitamin D) contribute to the generation of reactive oxygen species (ROS), which are involved in ECM degradation and subsequently skin ageing [40].

Various factors such as growth factors and cytokines are essential in the processes of skin cell regeneration and rejuvenation, so an effective anti-ageing strategy would be an increased level of these factors in the skin.

PRP as a great source of growth factors, cytokines, and other biologically active substances associated with tissue regeneration and remodelling can be used as a safe and effective option to rejuvenate the skin. PRP by increasing the expression of matrix metalloproteinase (MMP) proteins, which have roles in the degradation of damaged

ECM components, causes remodelling of ECM and then a significant improvement in cellular proliferation and differentiation in skin [41]. Furthermore, PRP increases the secretion of hyaluronic acid, which by hydration makes skin more turgid and improves its elasticity [42] (Fig. 2).

### Hair Restoration

Various scientific articles have shown that PRP therapy is an efficient option for hair loss in both men and women, which by stimulating hair follicles, increases hair count, hair growth, and hair thickness. Among many types of hair loss, androgenetic alopecia (AGA, male pattern baldness), a very common type of hair loss and thinning, is the best subject to undergo PRP therapy [7, 43–48] (Fig. 3).

### Hand Rejuvenation

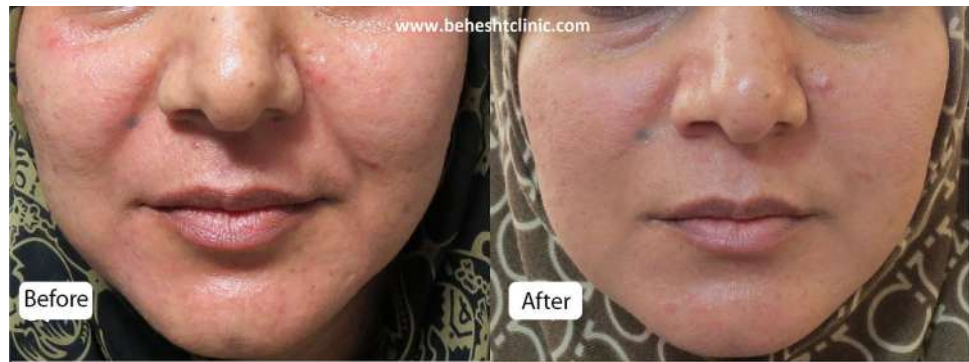Our hands are continuously exposed to sunlight and various chemicals, so they undergo ageing effects over time; thus, the number of people who are paying attention to the field of hand aesthetics and treatment options seems to increase. Nowadays, with the advent of PRP in various fields of aesthetic medicine it would be expected that this treatment might be useful for hand rejuvenation [49]. Hands as the most visible part of our body are affected by extrinsic and intrinsic ageing factors. Intrinsic factors, as a natural consequence of physiological effects over time, are contributors of decreasing skin elasticity, volume, structural integrity, and dermal vascularity. Finally, the results of these effects are skin hand thinning, wrinkles, prominent joints, tendons, and veins [50]. Extrinsic events vary from sunlight exposure, chemical damages such as pollution and smoking, lifestyle or diet. These factors by affecting epidermal and dermal layers of hand skin can cause various conditions including hypopigmentation, atopic dermatitis, actinic keratosis, and solar purpura [51].

Nowadays, there are various hand rejuvenation treatments such as mesotherapy (injections of medications, vitamins, plant extracts, etc.), micro-dermabrasion (removing dead layer of skin cells), laser, fat grafting, chemical peel (removing outer layers of the skin), and PRP therapy [52–54].

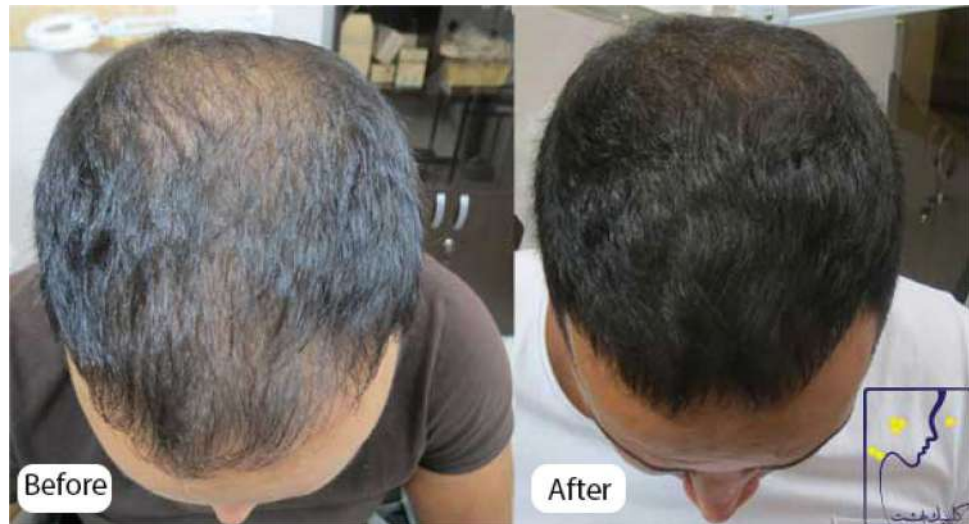Among these therapy options, PRP could be a favourable treatment, because of its safety (as a natural production) and effectiveness for body healing and repairing effects. However, although PRP treatment is well established and researched for hair restoration and non-healing wounds, in the field of hand rejuvenation, it seems that studies are limited, so it needs more attentions in the future. Since a few number of unpublished studies used PRP therapy for hand rejuvenation, clinical tests on PRP have shown improvement in the thickness, hydration, and



**Fig. 2** Significant improvement in facial skin by 2–6 weeks after PRP treatment. This figure has been taken from the Behesht clinic laboratory



**Fig. 3** Significant improvement in hair restoration by 2–6 weeks after PRP treatment. This figure has been taken from the Behesht clinic laboratory



softness of the hand skin after 3 or 4 month of treatment. Finally, a combination of PRP with dermal filler could help patients to achieve the best and longer results of hand rejuvenation [55–57].

### Breast Augmentation

Breast augmentation as an aesthetic procedure to enhance breast shape and increase its size is getting popular among women. Currently, traditional methods including breast augmentation with fat transfer and breast implant surgery are the most common and effective options. The use of PRP for breast augmentation as a novel option is going to be raised among women [58]. However, in relation to the effectiveness of PRP injections for breast enhancement, few scientific studies have been done yet, so it seems valuable to design more research for evaluating PRP therapy efficacy in breast augmentation.

Generally, there are two types of PRP therapy for breast augmentation procedures: (1) PRP in combination with fat transfer for breast enhancement (breast lift) and (2) the use of PRP alone for breast rejuvenation purposes [59].

Fat transfer as an effective method uses unwanted body fat (such as hips and thighs) and injects it into the breast area to increase its size. But there are some limitations such as reabsorption of fat by the body and also expansion of the breast, which can cause loss of sensitivity of the breast or nipple, due to the blockage of blood vessels [60]. Thus, to prevent such effects, it is necessary to have excess supplies of collagen and different growth factors in the area of the breast, and that is why aesthetic experts combine fat transfer with PRP to achieve excellent results. This combination not only increases the size of the breast, but also significantly improves its firmness, shape, and skin rejuvenation. Therefore, alongside with the safety of this procedure, there will be no more loss of sensitivity. Altogether, this method is a great option for women who lose their confidence because of their dropped and unnatural breast shape [58, 61].

Another option for the use of PRP is only for rejuvenation purposes, which is suitable for women who are satisfied with their breast size, but would like to have better looking and youthful breasts. In this method, various growth factors within PRP by inducing the production of new tissues, collagens, and blood vessels make the process

of breast rejuvenation longer lasting and more efficient than other options [26].

### Musculoskeletal rejuvenation/regeneration

Orthopaedic and musculoskeletal disorders caused either by ageing, trauma, or accidents are among the challenging conditions that can occur in muscle, tendon, bone, and ligament. In the USA, approximately 100 million office visits annually in orthopaedic clinics are for musculoskeletal injuries. Despite the traditional and common therapies for these problems which have not met with relative success, the use of platelet-rich plasma is now expanding as a desirable and effective therapeutic approach [62–65].

In recent years, the utilization of PRP as an augmentor of the natural healing response has demonstrated promising results in a shorter time period for the treatment of different musculoskeletal tissue injuries by producing stronger bone, regenerating muscle and tendon, and increasing tissue vascularity. Several studies have also reported great results of PRP treatment for relief from bone pain due to accidents and traumas [66–68]. For instance, in a study on 62 patients with chronic plantar fasciitis using PRP injection, results demonstrated that PRP can be used as an appropriate treatment to improve the pain of this disease during 6 months of treatment [69]. Similarly, the other studies also confirmed the relieving effect of PRP in the plantar fasciitis problem [70].

Several studies displayed the beneficial effect of PRP on osteoarthritis (OA) such as knee OA, hip OA, and shoulder OA compared to saline, hyaluronic acid, and corticosteroid treatments [62, 71–75]. Additionally, rotator cuff disorders, gluteal tendinopathy, and lateral epicondylalgia demonstrate greater success when utilizing PRP in comparison with other factors including corticosteroids regarding pain and function [76–79].

Furthermore, it was suggested that PRP could be used as an adjunct or therapeutic approach for other musculoskeletal conditions, orthopaedic surgery, and sport medicine, including hamstring injuries, elbow ulnar collateral ligament (UCL) injuries, anterior cruciate ligament (ACL) reconstruction, patellar tendinopathy, and achilles tendinopathy [80].

However, there is a need for further studies in musculoskeletal conditions. In the light of the available evidence, it can be suggested that PRP can be used as a therapeutic and complementary method for musculoskeletal conditions.

### Discussion

Several clinical studies have assessed the therapeutic efficiency of PRP on various conditions across different specialties including orthopaedics, dermatology, plastic surgery, aesthetic and regenerative medicine, paediatric surgery, urology, cardiac surgery, dentistry, and ophthalmology [81, 82]. The first study that applied PRP therapy in plastic surgery was done by Marx et al. in 1998, and showed that growth factors within PRP could quantifiably enhance regeneration of bone grafts compared to grafts without PRP use [83].

Here we summarized studies supporting the use of PRP in wound healing. In a study conducted by Suthar et al., in 24 patients with non-healing ulcers, treatment of PRP with single dose subcutaneous injections after 24 weeks affects wound healing and reduced wound size, pain, and inflammation [27]. In another study of 150 patients with foot ulcers due to diabetes, it has been demonstrated that PRP treatment after 4 weeks results in the reduction in wound size and improvement in healthy granulation tissue formation [84]. In this relation, Prabhu et al. also evaluated the efficacy of PRP in the treatment of 104 cases with chronic non-healing ulcers. They have shown that PRP treatment results in the healing of 81.73% patients (85 patients), whereas 12.5% of cases demonstrated healing with skin grafting. Therefore, PRP could be a safe and effective treatment option, which increases the healing rates of chronic wounds [85] (Table 2).

Therefore, the reason to consider implementation of PRP therapy in aesthetic and regenerative medicine is the fact that platelets can provide an effective and practical treatment option for conditions like wounds and ulcers [26, 30].

In various studies, it has been demonstrated that PRP may induce tissue expansion, skin proliferation, and rejuvenation. Here we addressed several clinical trials of PRP therapy for skin rejuvenation [19–23]. Cameli et al. in a clinical study on 12 healthy female volunteers have shown that PRP injections yielded significant improvement in skin texture through rejuvenation of facial skin [55]. Another prospective controlled clinical study conducted with injection of PRP in 20 women demonstrated an increase in dermal collagen production, which improved facial skin rejuvenation in a safe and efficient manner [86]. A further study on 20 women with facial wrinkles and nasolabial folds also showed that treatment with PRP for a period of 8 weeks resulted in improvement and correction of wrinkles of the nasolabial folds; thus, PRP therapy is considered as an appropriate and safe therapeutic way for face and nasal skin rejuvenation [87]. In another study, it was documented that PRP could significantly improve the

**Table 2** Evidence for the use of PRP in aesthetic and regenerative medicine

Study	Clinical application	Design/level of evidence	Doses of PRP	Follow-up	Results
Suthar et al. [27]	Wound healing	PRP treatment in 24 patients with non-healing ulcers/Level IV Evidence	3–4 mL	24 weeks	Reduction in wound size, pain and inflammation
Babaei et al. [84]	Wound healing	PRP treatment in 150 patients with foot ulcers due to diabetes/Level IV Evidence	2–4 mL	8 months	Reduction in wound size and improvement in healthy granulation tissue formation
Prabhu et al. [85]	Wound healing	PRP treatment in 104 cases with chronic non-healing ulcers/Level IV Evidence	NR (PRP dressing)	5 weeks	Significant improvement in the healing rates of chronic wounds
Willemssen et al. [118]	Facial lipofilling	PRP treatment in 32 cases underwent aesthetic facial lipofilling/Level II Evidence	3 cc mL	1 week, 3 months and 1 year	Significant decrease in recovery time
Cameli et al. [55]	Skin and facial rejuvenation	PRP treatment in 12 healthy volunteer women/Level IV Evidence	4 mL	3 months	Significant improvement in the skin texture, skin gross elasticity, and skin smoothness
Lee et al. [119]	Skin and facial rejuvenation	PRP treatment in 31 healthy volunteer women/Level II Evidence	4 mL	6 weeks	Significant increase in facial appearance and cheeks
Abuaf et al. [86]	Skin and facial rejuvenation	PRP treatment in 20 healthy volunteer women/Level IV Evidence	2 mL	4 weeks	Increase in dermal collagen production and improved facial skin rejuvenation.
Elnehrawy et al. [87]	Skin and facial rejuvenation	PRP treatment in 20 women with facial wrinkles and nasolabial folds/Level II Evidence	NR	8 weeks	Significant improvement and correction of wrinkles of the nasolabial folds in younger subjects
Uysal et al. [88]	Skin and facial rejuvenation	PRP treatment in patients with infraorbital hyperpigmentation (dark circles)/Level VI Evidence	NR	NR	Significant improvement in the pigmentation of skin lesions associated with a hyperpigmentation disorder
Rigotti et al. [89]	Skin and facial rejuvenation	Fat plus PRP treatment in 13 patients who were candidates for facelift/Level IV Evidence	NR	3 months	No significant difference between PRP and SVF-enriched fat
Hui et al. [90]	Skin and facial rejuvenation	PRP plus ultra-pulsed fractional CO2 laser therapy in 13 patients with facial ageing conditions/Level IV Evidence	2 mL	3 months	Improvement in facial wrinkles, skin texture, and skin elasticity
Asif et al. [92]	Skin and facial rejuvenation	PRP plus micro-needling in 50 patients with atrophic acne scars/Level III Evidence	2 mL (0.1 mL/cm <sup>2</sup> )	3 months	Significant reduction in scarring, wrinkles, and sun damages of the skin
Alves et al. [98]	Hair restoration	Treatment of PRP in half-head and the other half-head with placebo in 25 patients with AGA/Level III Evidence	0.15 mL/cm <sup>2</sup> (on 4 selected areas of the scalp)	6 months	Significant improvements in hair density and hair count compared to the control side
Shah et al. [99]	Hair restoration	Treatment of PRP plus minoxidil (5%) in 25 patients with AGA compared to the control group treated with minoxidil (5%) alone (25 cases)/Level II Evidence	0.05 mL/cm <sup>2</sup>	6 months	Significant improvement in hair growth and density in PRP plus minoxidil (5%)-treated group
Gentile et al. [100]	Hair restoration	A placebo-controlled study of PRP treatment in 23 AGA male subjects/Level II Evidence	0.1 ml/cm <sup>2</sup> (on selected areas of the scalp)	14 weeks	Significant improvement in hair growth, count and density
Singhal et al. [101]	Hair restoration	A placebo-controlled study of 20 participants with AGA (10 PRP-treated, 10 placebo)/Level II Evidence	Multiple small injections of 8–12 mL PRP	3 months	Significant improvement in hair counts, thickness, and root strength

**Table 2** continued

Study	Clinical application	Design/level of evidence	Doses of PRP	Follow-up	Results
Gentile et al. [58]	Breast augmentation	Treatment of PRP plus fat grafting in 50 patients with breast soft tissue defects compared to the control group treated with centrifuged fat grafting (50 patients)/Level IV Evidence	Combination of 0.5 mL of PRP with 1 mL of centrifuged fat tissue	36 weeks	Significant improvement in breast skin quality and softness, also 69% maintenance of the contour restoring in PRP- plus fat-treated group compared to fat grafting alone (39%)
Cervelli et al. [61]	Breast augmentation	Treatment of PRP plus fat grafting in 13 patients with breast soft tissue defects compared to fat-treated and 13 SVF-enhanced autologous fat graft-treated patients/Level IV Evidence	Combination of 0.4 mL of PRP with 1 mL of centrifuged fat tissue	30 months	69, 63, and 39% maintenance of contour restoring for PRP plus fat grafting, SVF-enhanced autologous fat grafts, and control group; therefore, PRP plus fat treatment has a better maintenance of breast volume

PRP platelet-rich plasma, P-PRP pure platelet-rich plasma, L-PRP leucocyte-platelet-rich plasma, PPP platelet-poor plasma, SVF stromal vascular fraction, AGA androgenetic alopecia, NR not reported

pigmentation in skin lesions associated with a hyperpigmentation disorder [88]. In another clinical trial conducted on 13 patients who were undergoing a facelift, it was reported that autologous fat grafting in combination with PRP could not provide significant improvement in skin rejuvenation over employing autologous expanded adipose-derived stem cells [89]. In a clinical trial by Hui et al., it was demonstrated that in 13 patients with facial ageing conditions, the use of PRP plus ultra-pulsed fractional CO<sub>2</sub> laser therapy for three months improved facial wrinkles, skin texture, and skin elasticity compared with the control group. So, the synergistic effect of PRP and ultra-pulsed fractional CO<sub>2</sub> laser yielded better therapeutic effects on the skin rejuvenation, while lowering side effects [90] (Table 2).

The combination of PRP therapy with micro-needling, another skin rejuvenation treatment which uses micro-needles to puncture hundreds of tiny micro-openings in the skin, has shown excellent responses in patients, to significantly reduce scarring, wrinkles, and sun damage of the skin. On the other hand, PRP therapy in conjunction with micro-needling, allows a better penetration of serum into the tiny holes (micro-openings) in the skin and flows to deep beneath the surface of the skin [91, 92] (Table 2).

Altogether, PRP by growing blood vessels and new collagen could help in the regeneration of damaged skin cells and reverse the processes of ageing, which makes it a great and new concept in aesthetic medicine [93–95]. So, PRP as a beneficial aesthetic and cosmetic treatment for skin rejuvenation can be used for the following: reducing sagging and wrinkles, mild collagen loss, skin tightening and toning, acne scars, crow's feet, and dark circles [54, 96, 97].

PRP therapy for hair loss is addressed in many studies. For instance, in a larger-scale study by Alves et al. three PRP treatment seasons with 1-month intervals on 25 patients with AGA have shown a significant increase in different phases of hair growth, including anagen, catagen, and telogen phases, which leads to final improvements in hair density and hair count compared to the control side [98].

Similarly, in an experimental study, including fifty patients with AGA, participants were equally divided into two groups, wherein the first group was treated with topical minoxidil (5%) alone and the second group minoxidil was treated in combination with PRP by micro-needling [99]. The study results after 6 months of treatment (interval of 1 month) indicated that the PRP-treated group in comparison with the first group provided a significant improvement in hair growth and density, which introduces PRP therapy as an effective, promising, and safe method for the treatment of AGA patients [99]. Furthermore, in a placebo-controlled study, 23 androgenic alopecia male subjects (3 were excluded at the end of the study) were treated with PRP. After 14 weeks (at 1-month intervals), favourable results of hair growth, count, and density were yielded [100]. Also, in another study consisting of 20 participants (10 PRP-treated, 10 placebo), subjects were injected with PRP at 3-week intervals. Results of 10 treated patients with PRP have shown an average reduction of 65% in hair loss during the test. At the end of study, all 10 patients had improved hair counts, thickness, and root strength [101] (Table 2). Generally, not all patients with hair loss are good candidates for PRP therapy, and only a small percentage of people could benefit from this kind of treatment, where people are with natural hair thinning and loss,



location-based hair loss, and those subjects who are totally healthy [102].

As mentioned, there are just several research experiments that have been published on PRP influence on fat grafting for breast augmentation purposes. Gentile et al. in a study of total 50 patients with breast soft tissue defects have shown that the use of fat grafting plus PRP yielded 69% maintenance of the contour restoration, while the control group with fat grafting alone demonstrated just 39% maintenance. Thus, fat grafting combined with PRP significantly improved maintenance of breast volume in women with breast soft tissue defects [58]. In another study conducted by Cervelli et al., the effects of fat grafting plus PRP on 13 patients with breast soft tissue defects compared with 13 SVF-enhanced autologous fat graft-treated patients were evaluated. Patients treated with PRP in combination with fat grafting showed 69% maintenance of contour restoration, while another group yielded 39% maintenance. Therefore, the use of both techniques produced significantly better maintenance of breast volume in these patients than fat grafting alone [61] (Table 2). For further support, in a study of PRP treatment plus autologous fat grafting on 40 patients (20 case, 20 control) results in the PRP-treated group showed significant improvement in fat grafting and reduction in fat absorption in 12 months after the operation, which introduced PRP as a reliable reconstruction option for breast augmentation [103].

In relation to hand rejuvenation, the injections of PRP could significantly stimulate angiogenesis and collagen synthesis and provide a firm, smooth, and youthful look. However, clinical studies in this regard are very limited. But the results with regard to the effect of PRP on the facial skin can be confirmed by the fact that this treatment will also be effective in hand rejuvenation. For instance, in an experimental study of 18 persons with photoaged skin on the dorsum of the hands, the application of PRP produced significant improvements in the Fitzpatrick wrinkle and elastosis scale and reduced the manifestations of skin ageing [104].

Studies in human muscle injury are few and of low methodical quality, and there are also contradictions. Some of these studies are the repair of muscle injuries including the repair of tendon [105], chondral injuries [106], bone regeneration [107], treatment of severe diabetic foot ulcers [108], and also plantar fasciitis [109]. Both clinical and experimental studies have revealed the effects of PRP treatment in muscle injuries, and generally, these studies have reported a better outcome in muscle regeneration/rejuvenation, reduced fibrosis, and increased neovascularization [110–114]. In this regard, in a study of 30 male professional athletes from Ukraine with acute local muscle injury, patients who received targeted PRP treatments had better pain relief in early assessments compared to the

conventionally treated group, but at 28 days, there was no difference between groups. Also, the mean time to return to sports was shorter in the treated versus control groups [115]. So, based on the growing evidence and despite the theoretical benefits of PRP to regenerate muscle tissues and fast return to activity, there is little scientific support for this intervention. Therefore, more studies are needed in this regard.

## Conclusion

PRP contains various bioactive proteins, growth factors, and interleukins associated with different cellular and biological process, i.e. cell proliferation, differentiation, and tissue reconstruction. Due to the unique characteristics of PRP, its use has been steadily increasing in recent years for aesthetic and cosmetic interventions. This bioactive material is studied in the fields of aesthetic interventions, both in vivo and clinical conditions. The results of these studies have revealed promising evidence as an effective option. On the other hand, treatment by PRP has shown itself as a bright future for a safe and efficient aesthetic and cosmetic intervention, particularly in wound healing, skin rejuvenation, hand rejuvenation, hair restoration, and breast augmentation. However, more studies are needed to better our understanding of limitations and benefits in clinical phases associated with the aesthetic and cosmetic use of PRP.

**Acknowledgements** We wish to express our sincere thanks to Dr. Roger S Hogue for his valuable comments.

## Compliance with Ethical Standards

**Conflict of interest** The authors declare that there is no conflict of interest.

## References

1. Kobayashi Y et al (2016) Leukocyte concentration and composition in platelet-rich plasma (PRP) influences the growth factor and protease concentrations. *J Orthop Sci* 21(5):683–689
2. Fitzpatrick J et al (2017) Analysis of platelet-rich plasma extraction: variations in platelet and blood components between 4 common commercial kits. *Orthop J Sports Med* 5(1):2325967116675272
3. Dhurat R, Sukesh M (2014) Principles and methods of preparation of platelet-rich plasma: a review and author's perspective. *J Cutan Aesthet Surg* 7(4):189
4. Fareed WM et al (2017) Efficacy of blood and its products-boon for oral surgeons. *J Univers Surg* 5(1):1–7
5. Cavallo C et al (2016) Platelet-rich plasma: the choice of activation method affects the release of bioactive molecules. *BioMed Res Int* 2016:1–7

6. Perez AG et al (2014) Relevant aspects of centrifugation step in the preparation of platelet-rich plasma. *ISRN Hematol* 2014:176060
7. Kumaran MS (2014) Platelet-rich plasma in dermatology: boon or a bane? *Indian J Dermatol Venereol Leprol* 80(1):5
8. Gentile P et al (2018) Mechanical and controlled PRP injections in patients affected by androgenetic alopecia. *JoVE* 131:e56406
9. Etulain J et al (2018) An optimised protocol for platelet-rich plasma preparation to improve its angiogenic and regenerative properties. *Sci Rep* 8(1):1513
10. Chicharro-Alcántara D et al (2018) Platelet rich plasma: new insights for cutaneous wound healing management. *J Funct Biomater* 9(1):10
11. Qian Y et al (2017) Platelet-rich plasma derived growth factors contribute to stem cell differentiation in musculoskeletal regeneration. *Front Chem* 5:89
12. Gentile P et al (2017) Concise review: the use of adipose-derived stromal vascular fraction cells and platelet rich plasma in regenerative plastic surgery. *Stem Cells* 35(1):117–134
13. Bottegoni C et al (2016) Homologous platelet-rich plasma for the treatment of knee osteoarthritis in selected elderly patients: an open-label, uncontrolled, pilot study. *Ther Adv Musculoskelet Dis* 8(2):35–41
14. Stessuk T et al (2016) Platelet-rich plasma (PRP) and adipose-derived mesenchymal stem cells: stimulatory effects on proliferation and migration of fibroblasts and keratinocytes in vitro. *Arch Dermatol Res* 308(7):511–520
15. Picard F et al (2017) Platelet-rich plasma-enriched autologous fat graft in regenerative and aesthetic facial surgery. *J Stomatol Oral Maxillofac Surg* 118(4):228–231
16. Hersant B et al (2016) Efficacy of autologous platelet-rich plasma glue in weight loss sequelae surgery and breast reduction: a prospective study. *Plastic Reconstruct Surg Glob Open* 4(11):e87
17. Sasaki GH (2016) Micro-needling depth penetration, presence of pigment particles, and fluorescein-stained platelets: clinical usage for aesthetic concerns. *Aesthet Surg J* 37(1):71–83
18. Jain NK, Gulati M (2016) Platelet-rich plasma: a healing virtuoso. *Blood Res* 51(1):3–5
19. Gawdat HI et al (2017) Autologous platelet-rich plasma versus readymade growth factors in skin rejuvenation: a split face study. *J Cosmet Dermatol* 16(2):258–264
20. Jee C-H et al (2016) Effect of autologous platelet-rich plasma application on cutaneous wound healing in dogs. *J Vet Sci* 17(1):79–87
21. Cieřlik-Bielecka A et al (2016) Benefit of leukocyte-and platelet-rich plasma in operative wound closure in oral and maxillofacial surgery. *BioMed Res Int* 2016:1–5
22. Rapisio E et al (2016) Adipose-derived Stem cells added to platelet-rich plasma for chronic skin ulcer therapy. *Wounds: Compend Clin Res Pract* 28(4):126–131
23. Fabbrocini G et al (2016) PRP for lip and eye rejuvenation. *Nonsurgical lip and eye rejuvenation techniques*. Springer, Berlin, pp 77–83
24. Masoudi EA et al (2016) Platelet-rich blood derivatives for stem cell-based tissue engineering and regeneration. *Curr Stem Cell Rep* 2(1):33–42
25. Bednarska K et al (2015) The use of platelet-rich-plasma in aesthetic and regenerative medicine. *MEDtube Sci* 3(1):8–15
26. Alexander RW (2010) Fat transfer with platelet-rich plasma for breast augmentation. In: Shiffman M (ed) *Autologous fat transfer*. Springer, Berlin, pp 243–259
27. Suthar M et al (2017) Treatment of chronic non-healing ulcers using autologous platelet rich plasma: a case series. *J Biomed Sci* 24(1):16
28. Carter MJ, Fylling CP, Parnell LK (2011) Use of platelet rich plasma gel on wound healing: a systematic review and meta-analysis. *Eplasty* 11:e38
29. Lacci KM, Dardik A (2010) Platelet-rich plasma: support for its use in wound healing. *Yale J Biol Med* 83(1):1
30. Moiola EK, Bolotin D, Alam M (2017) Regenerative medicine and stem cells in dermatology. *Dermatol Surg* 43(5):625–634
31. Kiritsi D, Nyström A (2018) The role of TGFβ in wound healing pathologies. *Mech Ageing Dev* 172:51–58
32. Barrientos S et al (2008) Growth factors and cytokines in wound healing. *Wound Repair Regen* 16(5):585–601
33. Rieger S et al (2015) The role of nuclear hormone receptors in cutaneous wound repair. *Cell Biochem Funct* 33(1):1–13
34. Park YG et al (2017) Hydrogel and platelet-rich plasma combined treatment to accelerate wound healing in a nude mouse model. *Arch Plastic Surg* 44(3):194
35. Mishra A, Woodall J, Vieira A (2009) Treatment of tendon and muscle using platelet-rich plasma. *Clin Sports Med* 28(1):113–125
36. Roy S et al (2011) Platelet-rich fibrin matrix improves wound angiogenesis via inducing endothelial cell proliferation. *Wound Repair Regen* 19(6):753–766
37. Kim DH et al (2011) Can platelet-rich plasma be used for skin rejuvenation? Evaluation of effects of platelet-rich plasma on human dermal fibroblast. *Ann Dermatol* 23(4):424–431
38. Mine S et al (2008) Aging alters functionally human dermal papillary fibroblasts but not reticular fibroblasts: a new view of skin morphogenesis and aging. *PLoS One* 3(12):e4066
39. Hsu Y-C, Li L, Fuchs E (2014) Emerging interactions between skin stem cells and their niches. *Nat Med* 20(8):847
40. Kammeyer A, Luiten R (2015) Oxidation events and skin aging. *Age Res Rev* 21:16–29
41. Browning SR et al (2012) Platelet-rich plasma increases matrix metalloproteinases in cultures of human synovial fibroblasts. *JBJS* 94(23):e172
42. Papakonstantinou E, Roth M, Karakiulakis G (2012) Hyaluronic acid: a key molecule in skin aging. *Dermato-endocrinology* 4(3):253–258
43. Khatu SS et al (2014) Platelet-rich plasma in androgenic alopecia: myth or an effective tool. *J Cutan Aesthet Surg* 7(2):107
44. Giordano S, Romeo M, Lankinen P (2017) Plated-rich plasma for androgenetic alopecia: does it work? Evidence from meta analysis. *J Cosmet Dermatol* 16:374–381
45. Ferneini EM et al (2017) Platelet-rich plasma in androgenic alopecia: indications, technique, and potential benefits. *J Oral Maxillofac Surg* 75(4):788–795
46. Gupta A, Carviel J (2017) Meta-analysis of efficacy of platelet-rich plasma therapy for androgenetic alopecia. *J Dermatol Treat* 28(1):55–58
47. Sheykhhasan M, Bakhtiari Pak H, Ghiasi M (2016) Autologous platelet-rich plasma (PRP) for the treatment of pattern hair loss: a review. *J Dermatol Cosmet* 7(3):169–185
48. Badran KW, Sand JPJFPC (2018) Platelet-rich plasma for hair loss: review of methods and results. *Fac Plastic Surg Clin* 26(4):469–485
49. Farage M et al (2008) Intrinsic and extrinsic factors in skin ageing: a review. *Int J Cosmet Sci* 30(2):87–95
50. Naylor EC, Watson RE, Sherratt MJ (2011) Molecular aspects of skin ageing. *Maturitas* 69(3):249–256
51. Drakaki E, Dessinioti C, Antoniou CV (2014) Air pollution and the skin. *Front Environ Sci* 2:11
52. Ganceviciene R et al (2012) Skin anti-aging strategies. *Dermato-endocrinology* 4(3):308–319

53. Skoczyńska A et al (2015) New look at the role of progerin in skin aging. *Przegląd menopauzalny=Menopause review* 14(1):53
54. Amini F et al (2015) Efficacy of platelet rich plasma (PRP) on skin rejuvenation: a systematic review. *Iran J Dermatol* 18:119–127
55. Cameli N et al (2017) Autologous pure platelet-rich plasma dermal injections for facial skin rejuvenation: clinical, instrumental, and flow cytometry assessment. *Dermatol Surg* 43(6):826–835
56. Kühne U, Imhof M (2012) Treatment of the ageing hand with dermal fillers. *J Cutan Aesthet Surg* 5(3):163–169
57. Charles-de-Sá L et al (2017) Effect of use of platelet-rich plasma (PRP) in skin with intrinsic aging process. *Aesthetic Surg J* 38(3):321–328
58. Gentile P, Cervelli V (2016) Breast reconstruction with autologous fat graft mixed with platelet-rich plasma. In: Shiffman M (ed) *Breast reconstruction*. Springer, Berlin, pp 231–241
59. Serra-Mestre JM et al (2014) Platelet-rich plasma mixed-fat grafting: a reasonable pro-survival strategy for fat grafts? *Aesthetic Plast Surg* 38(5):1041–1049
60. Parrish JN, Metzinger SE (2010) Autogenous fat grafting and breast augmentation: a review of the literature. *Aesthetic Surg J* 30(4):549–556
61. Cervelli V, Gentile P (2016) The combined use of enhanced stromal vascular fraction and platelet-rich plasma improves fat grafting maintenance in breast reconstruction: a comparative translational study. In: *Breast Reconstruction*. Springer, Berlin, pp 273–287
62. Kolber MJ et al (2018) Platelet rich plasma: basic science and biological effects running title platelet rich plasma overview. *Strength Cond J* 40:77–94
63. Amable PR et al (2013) Platelet-rich plasma preparation for regenerative medicine: optimization and quantification of cytokines and growth factors. *Stem Cell Res Therapy* 4(3):67
64. Lana JFSD et al (2017) Contributions for classification of platelet rich plasma—proposal of a new classification: mARSPILL. *Regen Med* 12(5):565–574
65. Mussano F et al (2016) Cytokine, chemokine, and growth factor profile of platelet-rich plasma. *Platelets* 27(5):467–471
66. Mishra A, Pavelko TJTJAJOSM (2006) Treatment of chronic elbow tendinosis with buffered platelet-rich plasma. *Am J Sports Med* 34(11):1774–1778
67. Shen L et al (2017) The temporal effect of platelet-rich plasma on pain and physical function in the treatment of knee osteoarthritis: systematic review and meta-analysis of randomized controlled trials. *J Orthop Surg Res* 12(1):16
68. Prodromos CC et al (2018) Intra-articular laser treatment plus Platelet Rich Plasma (PRP) significantly reduces pain in many patients who had failed prior PRP treatment. In *Proceedings of SPIE*, vol 2018
69. Gopinath S, Gudi N, Das S (2018) A study of outcome of autologous platelet rich plasma injection in patients with chronic plantar fasciitis. *Int J Orthop* 4(1):940–943
70. Barrett BSL, Erredge SE (2004) Feature: growth factors for chronic plantar fasciitis. *Podiatry Today-ISSN* 17:1045–7860
71. Dai W-L et al (2017) Efficacy of platelet-rich plasma in the treatment of knee osteoarthritis: a meta-analysis of randomized controlled trials. *Arthrosc: J Arthrosc Rel Surg* 33(3):659–670
72. Joshi Jubert N et al (2017) Platelet-rich plasma injections for advanced knee osteoarthritis: a prospective, randomized, double-blinded clinical trial. *Orthop J Sports Med* 5(2):2325967116689386
73. Doria C et al (2017) Treatment of early hip osteoarthritis: ultrasound-guided platelet rich plasma versus hyaluronic acid injections in a randomized clinical trial. *Joints* 5(3):152
74. Shen L et al (2017) The temporal effect of platelet-rich plasma on pain and physical function in the treatment of knee osteoarthritis: systematic review and meta-analysis of randomized controlled trials. *J Orthop Surg Res* 12(1):16
75. Kothari SY, Srikumar V, Singh N (2017) Comparative efficacy of platelet rich plasma injection, corticosteroid injection and ultrasonic therapy in the treatment of periarthritis shoulder. *J Clin Diagn Res: JCDR* 11(5):15
76. Shams A et al (2016) Subacromial injection of autologous platelet-rich plasma versus corticosteroid for the treatment of symptomatic partial rotator cuff tears. *Eur J Orthop Surg Traumatol* 26(8):837–842
77. Boesen AP et al (2017) Effect of high-volume injection, platelet-rich plasma, and sham treatment in chronic midportion Achilles tendinopathy: a randomized double-blinded prospective study. *Am J Sports Med* 45(9):2034–2043
78. Fitzpatrick J et al (2018) The effectiveness of platelet-rich plasma injections in gluteal tendinopathy: a randomized, double-blind controlled trial comparing a single platelet-rich plasma injection with a single corticosteroid injection. *Am J Sports Med* 46(4):933–939
79. Wang J, Zhou Y, Nirmala X (2018) Tendinopathy and its treatment: the rationale and pitfalls in the clinical application of PRP. In: *Platelet rich plasma in orthopaedics and sports medicine*. Springer, Berlin, pp 191–209
80. Wang D, Rodeo SA (2017) Platelet-rich plasma in orthopaedic surgery: a critical analysis review. *JBJS Rev* 5(9):e7
81. Sheykhhasan M et al (2017) The use of platelet-rich plasma in intervertebral disc regeneration: a review of preclinical studies and clinical experiments. *Razi J Med Sci* 24(156):72–92
82. Ghiasi M et al (2016) The effects of synthetic and natural scaffolds on viability and proliferation of adipose-derived stem cells. *Front Life Sci* 9(1):32–43
83. Marx RE et al (1998) Platelet-rich plasma: growth factor enhancement for bone grafts. *Oral Surg Oral Med Oral Pathol Oral Radiol Endodontology* 85(6):638–646
84. Babaei V et al (2017) Management of chronic diabetic foot ulcers using platelet-rich plasma. *J Wound Care* 26(12):784–787
85. Prabhu R et al (2018) Efficacy of homologous, platelet-rich plasma dressing in chronic non-healing ulcers: an observational study. *Cureus* 10(2):1–10
86. Abuaf OK et al (2016) Histologic evidence of new collagen formulation using platelet rich plasma in skin rejuvenation: a prospective controlled clinical study. *Ann Dermatol* 28(6):718–724
87. Elnehrawy NY et al (2017) Assessment of the efficacy and safety of single platelet-rich plasma injection on different types and grades of facial wrinkles. *J Cosmet Dermatol* 16(1):103–111
88. Uysal CA, Ertas NM (2017) Platelet-rich plasma increases pigmentation. *J Craniofac Surg* 28(8):e793
89. Rigotti G et al (2016) Expanded stem cells, stromal-vascular fraction, and platelet-rich plasma enriched fat: comparing results of different facial rejuvenation approaches in a clinical trial. *Aesthet Surg J* 36(3):261–270
90. Hui Q et al (2017) The clinical efficacy of autologous platelet-rich plasma combined with ultra-pulsed fractional CO2 laser therapy for facial rejuvenation. *Rejuven Res* 20(1):25–31
91. Chawla S (2014) Split face comparative study of microneedling with PRP versus microneedling with vitamin C in treating atrophic post acne scars. *J Cutan Aesthet Surg* 7(4):209
92. Asif M, Kanodia S, Singh K (2016) Combined autologous platelet-rich plasma with microneedling versus microneedling with distilled water in the treatment of atrophic acne scars: a concurrent split-face study. *J Cosmet Dermatol* 15(4):434–443

93. Alves R, Grimalt R (2018) A review of platelet-rich plasma: history, biology, mechanism of action, and classification. *Skin Appendage Disord* 4(1):18–24
94. Sand JP et al (2017) platelet-rich plasma for the aesthetic surgeon. *Facial Plast Surg* 33(04):437–443
95. Oyunsai Khan S et al (2017) Morphometric study of facial wrinkles and aesthetic skin as dermaroller treatment combined with platelet rich plasma (PRP). *Diagnostic Pathology* 3(1)
96. Fabbrocini G et al (2011) Combined use of skin needling and platelet-rich plasma in acne scarring treatment. *Cosmet Dermatol* 24(4):177–183
97. Mehryan P et al (2014) Assessment of efficacy of platelet-rich plasma (PRP) on infraorbital dark circles and crow's feet wrinkles. *J Cosmet Dermatol* 13(1):72–78
98. ALVES R, Grimalt R (2016) Randomized placebo-controlled, double-blind, half-head study to assess the efficacy of platelet-rich plasma on the treatment of androgenetic alopecia. *Dermatol Surg* 42(4):491–497
99. Shah KB et al (2017) A comparative study of microneedling with platelet-rich plasma plus topical minoxidil (5%) and topical minoxidil (5%) alone in androgenetic alopecia. *Int J Trichol* 9(1):14
100. Gentile P et al (2015) The effect of platelet-rich plasma in hair regrowth: a randomized placebo-controlled trial. *Stem Cells Transl Med* 4(11):1317–1323
101. Singhal P et al (2015) Efficacy of platelet-rich plasma in treatment of androgenic alopecia. *Asian J Transfus Sci* 9(2):159
102. Kalra S, Mathur K (2017) Platelet-rich plasma (PRP) for hair. *Int J Eng Technol Sci Res* 4(6):88–93
103. Yuan Q et al (2016) Influence of platelet-rich plasma (PRP) on autologous fat grafting breast augmentation surgery. *Chin J Med Aesthet Cosmetol* 22(6):348–351
104. Cabrera-Ramírez J et al (2017) Platelet-rich plasma for the treatment of photodamage of the skin of the hands. *Actas Dermo-Sifiliográficas (English Edition)* 108(8):746–751
105. Sánchez M et al (2010) Ligamentization of tendon grafts treated with an endogenous preparation rich in growth factors: gross morphology and histology. *Arthrosc J Arthrosc Rel Surg* 26(4):470–480
106. Sun Y et al (2010) The regenerative effect of platelet-rich plasma on healing in large osteochondral defects. *Int Orthop* 34(4):589–597
107. Schnependahl J et al (2016) Synergistic effects of HBO and PRP improve bone regeneration with autologous bone grafting. *Injury* 47(12):2718–2725
108. Ahmed M et al (2017) Platelet-rich plasma for the treatment of clean diabetic foot ulcers. *Ann Vasc Surg* 38:206–211
109. Jain K, Murphy PN, Clough TMJTF (2015) Platelet rich plasma versus corticosteroid injection for plantar fasciitis: a comparative study. *Foot* 25(4):235–237
110. Hamid MSA et al (2012) Platelet-rich plasma (PRP): an adjuvant to hasten hamstring muscle recovery: a randomized controlled trial protocol (ISCRTN66528592). *BMC Musculoskeletal Disord* 13(1):138
111. Cianforlini M et al (2015) Effect of platelet rich plasma concentration on skeletal muscle regeneration: an experimental study. *J Biol Regul Homeost Agents* 29(4 Suppl):47–55
112. Andia I, Abate MJEEOBT (2015) Platelet-rich plasma in the treatment of skeletal muscle injuries. *Expert Opin Biol Ther* 15(7):987–999
113. Gigante A et al (2014) Platelet-rich fibrin matrix effects on skeletal muscle lesions: an experimental study. In: *Orthopaedic proceedings of the British editorial society of bone and joint surgery*
114. Dimauro I et al (2014) Platelet-rich plasma and skeletal muscle healing: a molecular analysis of the early phases of the regeneration process in an experimental animal model. *PLoS One* 9(7):e102993
115. Bubnov R, Yevseenko V, Semeniv IJMU (2013) Ultrasound guided injections of Platelets Rich Plasma for muscle injury in professional athletes. *Comp Study* 15(2):101–105
116. Du L et al (2018) A novel and convenient method for the preparation and activation of PRP without any additives: temperature controlled PRP. *BioMed Res Int* 2018:1–12
117. Hamid MSA (2018) Cost effectiveness of a platelet-rich plasma preparation technique for clinical use. *Wounds: Compend Clin Res Pract* 30(7):186
118. Willemsen JC et al (2018) The addition of platelet-rich plasma to facial lipofilling: a double-blind, placebo-controlled, randomized trial. *Plast Reconstr Surg* 141(2):331–343
119. Lee ZH et al (2018) Platelet rich plasma for photodamaged skin: a pilot study. *J Cosmet Dermatol*. <https://doi.org/10.1111/jocd.12676>